



## Original article

# Acceleration of orthodontic treatment with the implementation of flexicorticotomy

## *Aceleração do tratamento ortodôntico com a implementação da flexicorticotomia*

Angie Paola Jimenez Gonzalez<sup>1</sup>  e Antonio Diaz Caballero<sup>1</sup> 

<sup>1</sup>University of Cartagena, Cartagena, Bolivar, Colombia.

### Abstract

**Objective:** to report a clinical case where it is demonstrated that the use of flexicorticotomy as an adjuvant in orthodontic treatments show results in less time in patients with the presence of thin alveolar ridges. **Description of the case:** a 35-year-old female patient with the presence of gaps from 33 to 36 and from 43 to 46 with formation of the so-called "bottlenecks" as a residual effect of their extraction. **Results:** the formation of trabecular bone was observed radiographically and through tomography the recovery and formation of the necessary space to be able to perform dental movements, closing the gaps. **Conclusion:** flexicorticotomy shows excellent results as an adjuvant in dental movements exerted by orthodontic forces in cases where the space between the two cortices is very small, causing dental replacements to be affected, therefore performing a controlled fracture to generate the necessary space between the two bony tables, it will facilitate previously obstructed tooth movement.

**Keywords:** Expansion. Flanges. Bone transplant. Platelet-rich fibrin.

### Resumo

**Objetivo:** relatar um caso clínico onde é demonstrado que o uso da flexicorticotomia como adjuvante nos tratamentos ortodônticos apresenta resultados em menor tempo em pacientes com presença de rebordos alveolares finos. **Descrição do caso:** paciente do sexo feminino, 35 anos, com presença de diastemas de 33 a 36 e de 43 a 46 com a formação dos chamados "gargalos" como efeito residual de sua extração. **Resultados:** observou-se radiograficamente a formação de osso trabecular e por meio de tomografia a recuperação e formação do espaço necessário para realizar os movimentos dentários, fechando os diastemas. **Conclusão:** a flexicorticotomia apresenta excelentes resultados como adjuvante nas movimentações dentárias exercidas por forças ortodônticas nos casos em que o espaço entre as duas corticais é muito pequeno, fazendo com que as reposições dentárias sejam afetadas, realizando assim uma fratura controlada, para gerar um espaço necessário entre as mesas ósseas, facilitará a movimentação dentária anteriormente obstruída.

**Palavras-chave:** Expansão. Flanges. Transplante ósseo. Fibrina rica em plaquetas.

**Corresponding author:** Angie Paola Jimenez Gonzalez | [ajimenezg@unicaratagena.edu.co](mailto:ajimenezg@unicaratagena.edu.co)

**Received in:** 21|10|2022. **Approved in:** 09|02|2023.

**How to cite this article:** Gonzalez APJ, Caballero AD. Acceleration of orthodontic treatment with the implementation of flexicorticotomy. Revista Bionorte. 2023 jan-jun;12(1):326-32.

<https://doi.org/10.47822/bn.v12i1.575>





## Introduction

In the process of growth and development of the dental organs and their jaws, alterations can be generated that can affect a correct occlusion. For the correction and improvement of this, over time treatments such as orthodontics have been developed, which may present limitations in adulthood due to cellular aging and little bone remodeling, obtaining better results during puberty<sup>1</sup>.

Orthodontics is the study of malocclusion, anomalies in the shape, position, and functions of the dentomaxillofacial structural component, where it is sought to give a correct diagnosis and subsequently the appropriate treatment. Being its daily exercise to prevent, diagnose and correct its possible alterations, staying within an optimal state of health and harmony, through the use and control of different types of forces<sup>2</sup>.

To start an orthodontic treatment, it is ideal that it be carried out at an optimal time<sup>3</sup> that can guarantee excellent results in the shortest possible time, without altering other structures such as: loss of supporting tissue, resorption of dental roots, among others. The ideal or recommended age for carrying out an orthodontic treatment is in the growth stage, where the alveolar bone and the supporting tissues of the tooth are in development, which will facilitate the traction of the dental organs, this process takes place until approximately the age of fourteen. From then on, mainly in adulthood, the adaptation of the teeth to the changes and bone turnover in the alveolar bone that are artificially caused by the forces exerted by orthodontics are more complicated, but not impossible. Concluding, better results and greater ease of dental movement will be obtained in children<sup>4</sup>.

Over the years, they present certain physiological changes that make it difficult to correct dental positions, such as the condemnation of the bone due to age or because the cortical tables are very thin, due to this, dental extractions<sup>5</sup> can produce a narrowing of the alveolar ridges, resulting in diastemas that are impossible to close with orthodontics, for which reason flexicorticotomy should be used as an adjuvant surgical treatment for this<sup>6</sup>.

Flexicorticotomy is a surgical procedure that is used mainly in edentulous patients with reduction of the cortices that require dental implants, but it can also be taken as an adjuvant treatment to facilitate orthodontic treatment in patients older than 14 years, where there is no movement due to the reduction in the efficiency of the tissues, for this an incision is made in the alveolar crest, with the purpose of separating the vestibular and lingual/palatal cortices to create space for a dental implant or dental movement<sup>7</sup>.

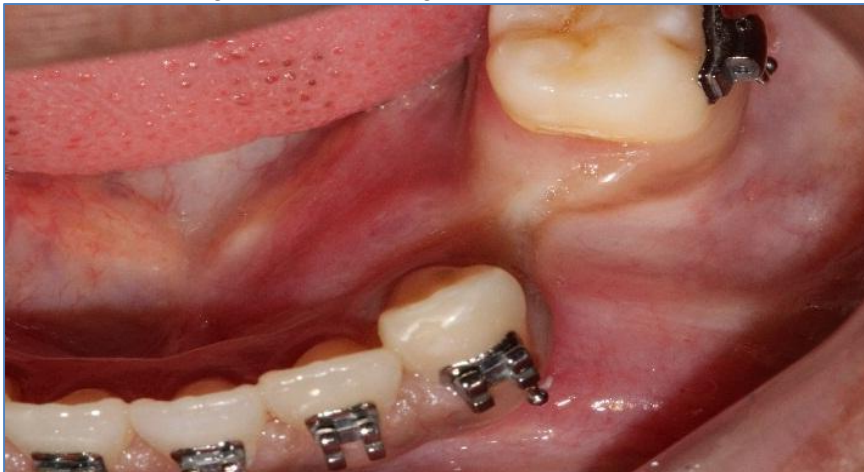The importance of publishing this kind of documents lies in the possibility of using flexicorticotomy as a therapeutic tool to facilitate dental movement in orthodontic treatments, in anatomical areas with bone resorption or bottlenecks, which prevent teeth from moving naturally.

The objective of this clinical case report is to expose a case where the flexicorticotomy surgical technique was used to facilitate dental movement with orthodontic appliances and to demonstrate the success of the use of this technique as an adjuvant in patients with bone resorption in edentulous spaces where they did not present the sufficient space for orthodontic tooth movement.

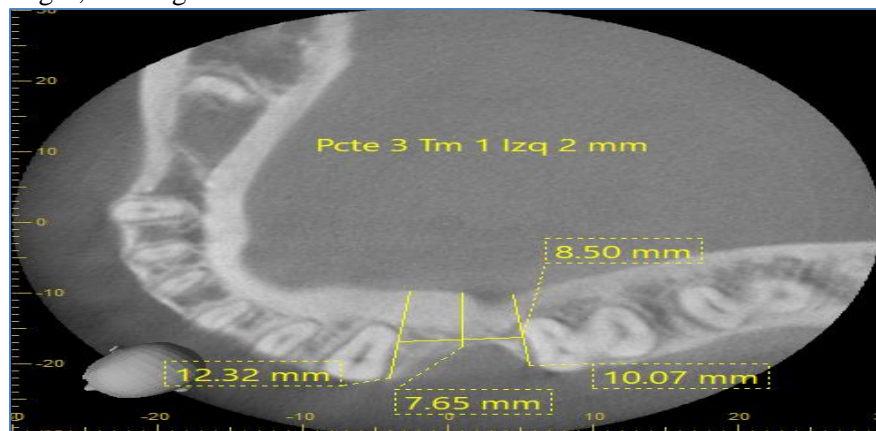
## Case report

A 35-year-old female patient, consults to continue her orthodontic treatment at the University of Cartagena, Colombia. No relevant medical history was reported and in the intraoral examination, from dental organs 33 to 36 and from dental organs 43 to 46 due to extraction of the same, generating a narrowing between the vestibular and palatal cortices, preventing the mobilization of the teeth and decreasing the diastema.

**Figure 1.** Presence of a gap between the first lower left molar and lower left canine, due to the absence of the two left premolars. Note the collapse of the alveolar ridge in the buccolingual direction.



**Figure 2.** Tomography of the lower jaw. The residual space is observed due to the extraction of the two left premolars and the reduction of the alveolar ridges, forming the so-called "bottlenecks".



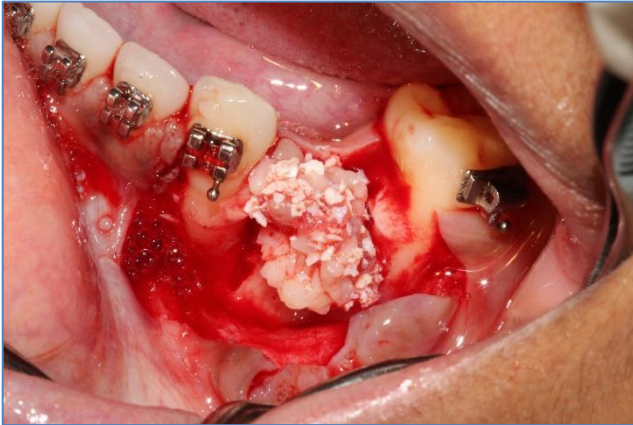
Once the case was presented, with the relevant information and study of the same, a treatment plan was indicated, which was to perform flexicorticotomy with bone filling. Post-surgical follow-up, suture removal and a monthly control were performed.

To carry out the surgical procedure, an incision was made in the alveolar crest, dissecting the periosteum of the area, including vestibular and lingual dissection and a certain part of the adjacent dental organs, leaving the cortical bone denuded. After this, with a high-speed handpiece, diamond bur, bone expanders and hammer, a controlled greenstick fracture was made, forming a space, obtaining 0.4 mm width and 0.6 mm diameter depth.

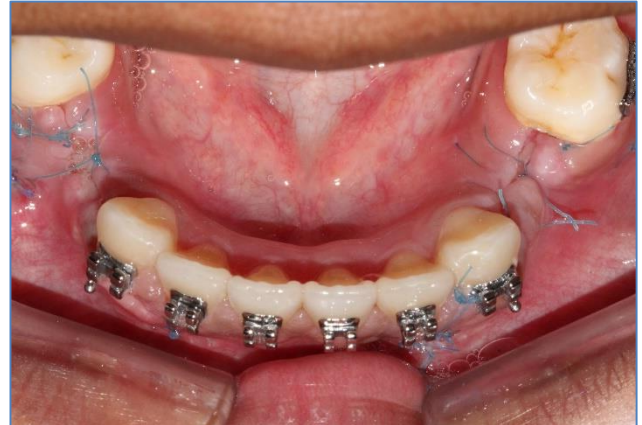In the space between the two vestibular and lingual bone tables obtained, a filling was made with heterologous bone graft, Criteria lumina bone porous®, together with platelet-rich fibrin, which provides structural support that will help the new bone formation from the mesenchymal cells that will help in the synthesis of the new bone.

The flaps are sutured, avoiding tensions in the soft tissue, with 6-0 nylon. Amoxicillin 500 mg capsules were prescribed every eight hours for seven days, and Celecoxib 200 mg tablets for 5 days for pain management. The sutures were removed after 10 days<sup>8</sup>.

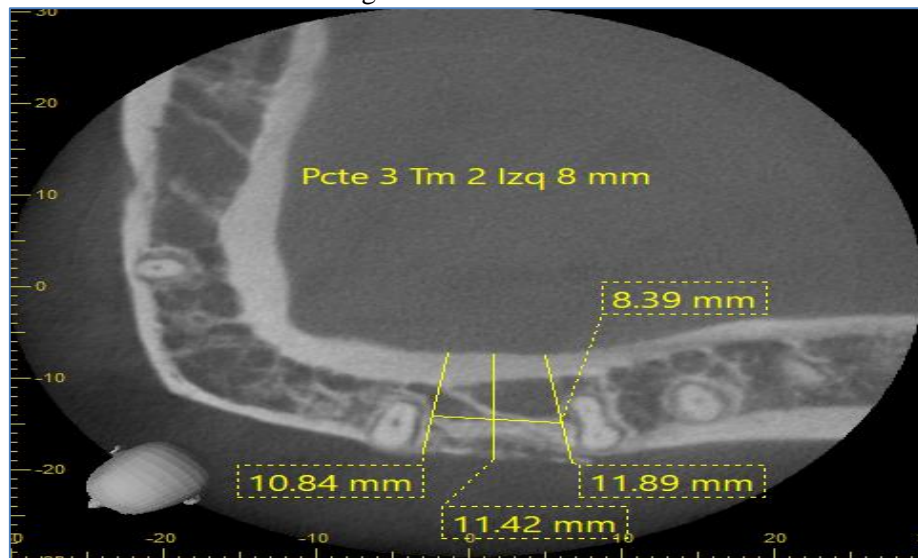
**Figura 3.** Heterologous bone graft, criterio lumina bone porous®, together with platelet-rich fibrian.



**Figure 4.** Suture in an occlusal view with nylon 6-0



**Figure 4.** Tomography of the lower jaw, showing an increase in the Space between the vestibular and lingual cortices.



## Discussion

In cases of adult patients with a history of dental extractions without prosthesis, over the years, physiologically bone resorption occurs which can produce narrow and compact alveolar ridges, forming what are called “bottlenecks”, which are a residual edge defect, preventing dental implants or preventing dental movements of orthodontic treatments to reduce the spaces created by dental extractions. Faced with similar situations, Selcuk Basa, Altan Varol, and Neslihan Turker, made different alternatives for the bone expansion of the alveolar ridges, exposed in their article; likewise, they performed a flexicorticotomy, as an adjuvant treatment to orthodontic treatment, as described in this clinical case report<sup>9</sup>.



Gonzalez APJ, Caballero AD.

The beginning of an orthodontic treatment can be prolonged and tedious, even more if it is in adults, however, if the use of orthodontic forces combined with a surgical procedure is implemented, it favors the movements of the dental organs and decreases the time of use of orthodontic appliances, as expressed by George A and colleagues in their article<sup>3</sup>.

The implementation of flexicorticotomy as an adjuvant surgical procedure in the previously exposed clinical case, presented a great advantage, achieving dental movements that were impossible due to the lack of space between the corticals without producing dental resorptions, greatly facilitating the formation and bone repair, which can be observed by trabecular bone formation through radiography and histological studies, as observed and mentioned by Simion, Baldon and Zaffe in their article<sup>9</sup>.

## Conclusion

As we have been able to demonstrate previously, flexicorticotomy is a surgical process used to create space between the two cortices in order to place implants as a solution to the absence of a dental organ. However, as already described and reported in this clinical case, flexicorticotomy can also be used as a complementary surgery in orthodontic treatments to facilitate dental movements when there is not enough space for said dental repositioning, due to the little space that is present in the so-called "bottlenecks". Therefore, this surgery is of great help when it comes to generating the missing space to facilitate the necessary dental movements through the different forces exerted by orthodontics.

## Contribution of the authors

All authors approved the final version of the manuscript and declared themselves responsible for all aspects of the work, including guaranteeing its accuracy and integrity.

## Conflict of interest

The authors declare not to have any interest conflicts.

## References

1. Kuitert RB. Orthodontic treatment for adults. *Ned Tijdschr Tandheelkd* [Internet]. 2000;107(4):160-8. Available from: <https://pubmed.ncbi.nlm.nih.gov/11382973/>



Gonzalez APJ, Caballero AD.

2. Jahanbin A, Hasanzadeh N, Khaki S, Shafae H. Comparison of self-ligating Damon3 and conventional MBT brackets regarding alignment efficiency and pain experience: A randomized clinical trial. *J Dent Res Dent Clin Dent Prospects* [Internet]. 2019;13(4):281-8. Available from: <https://pubmed.ncbi.nlm.nih.gov/32190212/>
3. Mandelaris GA, DeGroot BS, Relle R, Shah B, Huang I, Vence BS. Surgically Facilitated Orthodontic Therapy: Optimizing Dentoalveolar Bone and Space Appropriation for Facially Prioritized Interdisciplinary Dentofacial Therapy. *Compend Contin Educ Dent* [Internet]. 2018. Available from: <https://pubmed.ncbi.nlm.nih.gov/29493244/>
4. Charavet C, Lambert F, Lecloux G, Le Gall M. Accelerated orthodontic treatment using corticotomies: what are the minimally invasive alternatives?. *Orthod Francaise* [Internet]. 2019;90(1):5-12. Available from: [https://www.jle.com/fr/revues/odf/e-docs/traitement\\_orthodontique\\_accelere\\_par\\_corticotomies\\_quelles\\_sont\\_les\\_alternatives\\_minimal\\_ement\\_invasives\\_\\_318075/article.phtml](https://www.jle.com/fr/revues/odf/e-docs/traitement_orthodontique_accelere_par_corticotomies_quelles_sont_les_alternatives_minimal_ement_invasives__318075/article.phtml)
5. Zucchelli G, Sharma P, Mounssif I. Esthetics in periodontics and implantology. *Periodontol 2000* [Internet]. 2018;77(1):7-18. Available from: <https://onlinelibrary.wiley.com/doi/10.1111/prd.12207>
6. Mota-Rodríguez AN, Olmedo-Hernández O, Argueta-Figueroa L. A systematic analysis of evidence for surgically accelerated orthodontics. *J Clin Exp Dent* [Internet]. 2019;11(9):e829-38. Available from: <https://www.ncbi.nlm.nih.gov/pmc/articles/PMC6797450/>
7. Herrera A, Simanca-Pallares M, Diaz A. Uso de la Flexicorticotomia como técnica quirúrgica coadyuvante para el tratamiento de ortodoncia [Internet]. *Acta de odontologica venezolana*. 2021. Available from: <https://www.actaodontologica.com/ediciones/2011/4/art-18/>
8. Basa S, Varol A, Turker N. Alternative bone expansion technique for immediate placement of implants in the edentulous posterior mandibular ridge: a clinical report. *Int J Oral Maxillofac Implants* [Internet]. 2004;19(4):554-8. Available from: <https://pubmed.ncbi.nlm.nih.gov/15346753/>
9. Zimmo N, Saleh MHA, Mandelaris GA, Chan HL, Wang HL. Corticotomy-Accelerated Orthodontics: A Comprehensive Review and Update. *Compend Contin Educ Dent Jamesburg NJ* 1995 [Internet]. 2017;38(1):17-25. Available from: <https://pubmed.ncbi.nlm.nih.gov/28054789/>